



Cardiovascular complications of COVID-19 vaccines: A review of case-report and case-series studies

Mohammad Hossein Paknahad, M.D.^a, Fatereh Baharlouei Yancheshmeh, M.D.^a,
Azam Soleimani, M.D.^{b,c,*}

^a Cardiologist, Cardiology Department, Chamran Cardiovascular Medical and Research Hospital, Isfahan University of Medical Sciences, Isfahan, Iran

^b Associate Professor of Cardiology, Echocardiologist, Cardiac Rehabilitation Research Center, Isfahan Cardiovascular Research Institute, Isfahan University of Medical Sciences, Isfahan, Iran

^c Echocardiography Department, Chamran Cardiovascular Medical and Research Hospital, Isfahan University of Medical Sciences, Isfahan, Iran

ARTICLE INFO

Article History:

Received 22 July 2022

Revised 24 January 2023

Accepted 5 February 2023

Available online 8 February 2023

Keywords:

COVID-19

mRNA vaccine

Adenoviral vector vaccine

Inactivated vaccine

Cardiovascular complications

Review

ABSTRACT

Background: There are multiple reviews on cardiovascular aspects of COVID-19 disease on cardiovascular system in different population but there is lack of evidence about cardiovascular adverse effects of COVID vaccines.

Objectives: The purpose of this study was to compare the cardiac complications of COVID19 vaccines, based on vaccine type (mRNA, vector-based, and inactivated vaccines).

Methods: A systematic search was performed covering PubMed for English case-reports and case-series studies, and finally 100 studies were included.

Results: Myocarditis (with overall rate around 1.62%) was shown to be the most common post-COVID19 immunization cardiac event. More than 90% of post-COVID19 vaccination myocarditis occurred after receiving mRNA vaccines (Moderna & Pfizer-BioNTech), but the report of this event was less in the case of vector-based vaccinations and/or inactivated vaccines. Myocarditis was reported more commonly in men and following the second dose of the immunization. Takotsubo cardiomyopathy (TTC) was reported after mRNA (more commonly) and vector-based vaccinations, with no case report after inactivated vaccines. When mRNA and vector-based vaccinations were used instead of inactivated vaccines, a greater frequency of vaccine-induced thrombotic thrombocytopenia (VITT) and pulmonary emboli (PE) was reported. Myocardial infarction/cardiac arrest was recorded in those beyond the age of 75 years.

Conclusion: The personal and public health benefits of COVID-19 vaccination much outweigh the minor cardiac risks. Reporting bias, regarding more available mRNA vaccines in developed countries, may conflict these results.

© 2023 Elsevier Inc. All rights reserved.

Introduction

The new coronavirus is known as “Severe Acute Respiratory Syndrome Corona Virus 2 (SARS-CoV2)”, responsible for COVID-19 disease originated in China in 2019 and rapidly became a pandemic. Soon after vaccination was started and till now, 38 types of vaccines are approved in different countries.^{1–3} The development of an effective vaccine against the SARS-CoV-2 virus that causes COVID-19 disease has been proven to be a vital tool in controlling the high pandemic’s spread and its enormous effects.⁴ Multiple coronavirus vaccines are currently being developed, including the mRNA-1273 (Moderna), mRNA vaccines BNT162b2 (Pfizer-BioNTech/Comirnaty),

adenoviral vector vaccine: Ad26.COVS.2 (Johnson & Johnson/Janssen), AZD1222 (Oxford-AstraZeneca/Covidshield) and the inactivated vaccines: CoronaVac (Sinovac Bio (Sputnik V) and WIBP / BBIBP-CorV COVID-19 vaccine (Sinopharm).⁵

Safety monitoring is an important part of ensuring comprehensive and effective vaccination.⁶ Safe and effective vaccination is vital to eliminating the SARS-CoV-2 pandemic; however, a substantial number of patients have underlying cardiovascular disease and/or risk factors for heart disease. There are multiple reviews on the effects of COVID-19 disease on the cardiovascular system in different populations but there is a lack of evidence about the cardiovascular adverse effects of COVID vaccines.^{1,2} Some significant cardiovascular adverse effects are linked to COVID-19 immunization, such as the development of myocarditis, pericarditis, or *peri* myocarditis.^{5,7–12} Because of the small sample size, tight inclusion criteria, short follow-up periods, and trial participants who may not be the same as the general

* Corresponding author at: Associate Professor of Cardiology, Cardiac Rehabilitation Research Center, Isfahan Cardiovascular Research Institute, Isfahan University of Medical Sciences, Isfahan, Iran.
E-mail addresses: asoleimani@gmail.com, a_soleimani@mui.ac.ir (A. Soleimani).

population who will receive the vaccination, rare or serious vaccine effects may be undetected in phase 3 trials.¹³ Although pericarditis and myocarditis were not reported as side effects in COVID-19 vaccine in clinical trials, there have been multiple reports of probable cases in the general population following immunization.¹⁴ Systematic reviews of case reports are used to summarize current scientific knowledge about rare events.¹⁵ It has been believed that in the case of relatively rare events such as cardiovascular-related side effects of COVID-19 vaccines, case reports and case series studies may provide important evidence for systematic reviews. Hence in the present systematic review, we aimed to collect and analyze the case-report and case-series studies on all types of commonly used mRNA, vector-based and inactivated COVID-19 vaccines to compare cardiovascular adverse effects between different types of these vaccines.

Methods

PRISMA 2020 standards for reporting systematic reviews and meta-analyses were followed in this study.¹⁶ All three writers conducted and assessed the initial search, screening, and eligibility of the publications, and any disputes were handled by consensus.

Literature search

We performed a search on PubMed for articles reported cardiac complications of mRNA vaccine: BNT162b2 (Pfizer-BioNTech/Comirnaty) and mRNA-1273 (Moderna), and Vector vaccine: AZD1222 (Oxford-AstraZeneca/Covidshield), Ad26.COV2.S (Johnson & Johnson/Janssen), Gam-COVID-Vac (Sputnik V), and JNJ-78,436,735 (Johnson & Johnson). The search strategy in PubMed was as follows:

(("vaccine*" [Title/Abstract])) OR (Vaccines [MeSH Terms]) OR (jab [Title/Abstract]) OR (Immunization [Title/Abstract]) OR (Immunization [MeSH Terms]) OR (Vaccination [MeSH Terms]) OR (Vaccination [Title/Abstract]) OR (injection [Title/Abstract]) OR (injections [MeSH Terms]) OR (BioNTech [Title/Abstract]) OR (Pfizer [Title/Abstract]) OR (Comirnaty [Title/Abstract]) OR (BNT162b2 [Title/Abstract]) OR ("BNT162 Vaccine" [Title/Abstract]) OR ("BNT162 Vaccine" [MeSH Terms]) OR (Moderna [Title/Abstract]) OR ("mRNA-1273" [Title/Abstract]) OR ("2019-nCoV Vaccine mRNA-1273" [MeSH Terms]) OR ("2019-nCoV Vaccine mRNA-1273" [Title/Abstract]) OR ("mRNA Vaccines" [Title/Abstract]) OR ("Johnson & Johnson" [Title/Abstract]) OR (Janssen [Title/Abstract]) OR (AstraZeneca [Title/Abstract]) OR ("ChAdOx1 nCoV-19" [Title/Abstract]) OR ("ChAdOx1 nCoV-19" [MeSH Terms]) OR (AZD1222 [Title/Abstract]) OR (Vaxzevria [Title/Abstract]) OR (Covishield [Title/Abstract]) OR ("Sputnik V" [Title/Abstract]) OR ("Gam-COVID-Vac" [Title/Abstract]) OR ("Gam-COVID-Vac vaccine" [Title/Abstract]) OR ("Gam-COVID-Vac vaccine" [MeSH Terms]) OR ("JNJ-78,436,735" [Title/Abstract]) OR (Ad26COVS1 [Title/Abstract]) OR (Ad26COVS1 [MeSH Terms]) OR ("Ad26.COV2.S" [Title/Abstract]) OR (Janssen [Title/Abstract]) OR ("Adenoviral vector" [Title/Abstract]) AND (heart [Title/Abstract]) OR (myocardial* [Title/Abstract]) OR (cardio* [Title/Abstract]) OR (coronary* [Title/Abstract]) OR (vascu* [Title/Abstract]) OR ("myocardial infarction" [Title/Abstract]) OR ("myocardial infarction" [MeSH Terms]) OR (heart [MeSH Terms]) OR (Cardiovascular [Title/Abstract]) OR ("Cardiovascular System" [MeSH Terms]) AND ("adverse events" [MeSH Terms]) OR ("adverse events" [Title/Abstract]) OR ("adverse effects" [Title/Abstract]) OR ("adverse effects" [MeSH Terms]) OR ("side effects" [MeSH Terms]) OR ("side effects" [Title/Abstract]) OR ("Complications" [Title/Abstract]) OR ("Complications" [MeSH Terms]) AND LitCCASEREPORT [filter]). We used a predefined filter of PubMed for identifying case report studies on COVID-19 regarding our search term.

Eligibility criteria and study selection

After the initial search, duplicate entries, reviews, clinical studies, clinical trials, and full-text articles that were unavailable were eliminated. We considered English case reports and case-series studies. Then, based on the title and abstract, the article records were evaluated and excluded if they had an unsuitable correlation with the current study keywords. The full-text papers were then evaluated for qualifying criteria (Table 1). Fig. 1 shows the study selection process.

Results and discussion

A total of 100 case reports or case series which reported cardiac complications after COVID-19 vaccination were included.^{17–117} The manifestations, treatment, and outcomes of cardiac complications of COVID-19 vaccination, are summarized in Table 2.

Myocarditis/pericarditis/myopericarditis

Myocarditis is defined as inflammation of the heart muscle (myocardium). Inflammation happens when the immune system responds to internal or external stimuli for example viral infections as well as more systemic inflammatory illnesses including autoimmune disorders.¹¹⁸ In myopericarditis, chest pain, increased levels of cardiac enzymes and electrocardiographic changes occur. Pericarditis is a somewhat prevalent cause of chest pain, and around 5% of all hospitalizations for chest pain are due to pericarditis.¹¹⁹ Myocarditis has been reported as a major side effect of these vaccines; however, the overall rate of post-COVID19 vaccination-myocarditis is around 1.62% which is very small.^{120–122}

mRNA vaccines

A study by Abu Mouch et al. reported 6 cases of myocarditis (5 cases after the second dose and 1 case after the first dose) with no evidence of COVID-19 infection, which occurred shortly after the mRNA vaccine Pfizer/BioNTech BNT162b2 injection. In their study, the diagnosis of myocarditis was established after cardiac MRI and all 6 cases were male.²⁹ Another study by Al-Rasbi et al. in Oman also reported a case of a 37-year-old male subject with myocarditis, who presented with pulmonary edema. He demonstrated severe multisystem involvement including thrombocytopenia, rhabdomyolysis, pulmonary hemorrhage, and non-oliguric acute kidney injury after the BNT162b2 mRNA vaccine.³⁴ Alania-Torres et al. reported another case of myocarditis in patients with arrhythmogenic left ventricular cardiomyopathy (ALVC) after mRNA vaccination against COVID-19.³⁵ A case of fatal fulminant necrotizing myocarditis also has been reported in New Zealand for a 57-year-old female, after receiving the first dose of the Pfizer-BioNTech vaccine.³⁶ A study from Korea reported a 22-year-old man who developed myocarditis 5 days after the first dose of the BNT162b2 mRNA vaccine and died 7 h later.⁴⁴ Myocarditis also occurred after mRNA COVID vaccines in paediatrics

Table 1
Eligibility criteria.

No.	Criteria	Description
1.	Study Design	Inclusion: Case-reports-case-series Exclusion: A review article, clinical study, clinical trials, cohort studies
2.	Population	Inclusion: People who received COVID-19 vaccination Exclusion: N/A*
3.	Intervention	Inclusion: COVID-19 vaccination Exclusion: N/A*
4.	Outcome	Inclusion: Cardiovascular events Exclusion: N/A*
5.	Language	Inclusion: English Exclusion: N/A*
6.	Time of Publication	Inclusion: No beginning date- January 2022 Exclusion: N/A*

*N/A; Not Applicable.

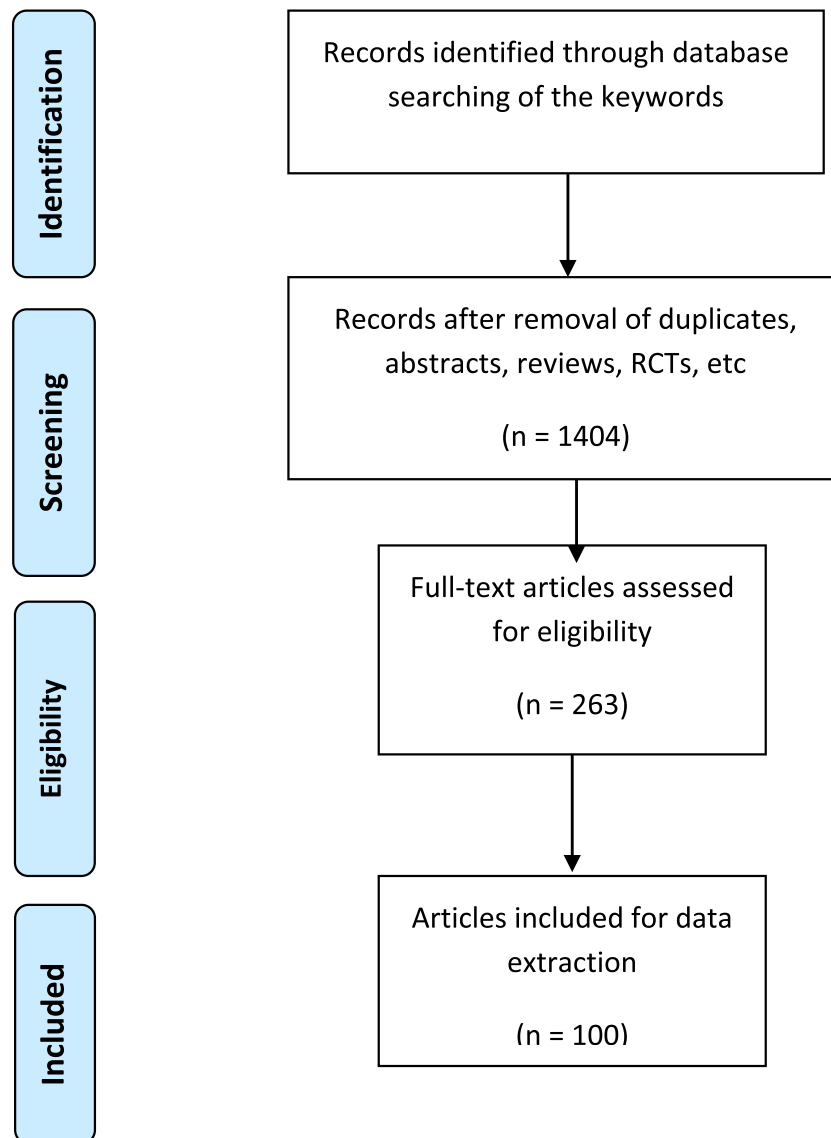


Fig. 1. Flowchart of study selection.

as reported for a 17 years old boy,⁸⁹ and a 14-year-old male subject.¹⁰⁸ Istampoulouglou et al. reported a series of 9 cases with perimyocarditis, 5 myocarditis cases, and 3 pericarditis cases.⁹⁵ Another case series study reported 9 cases of acute pericarditis of them seven received mRNA vaccines BNT162b2 and mRNA-1273, and 2 cases received AZD1222.⁹⁹ Several more case-report studies documented myocarditis or recurrence of acute myocarditis after receiving mRNA vaccination against COVID-19 infection.^{5,7–11,17,18,20,22,24,37–39,41–43,47–55,57–68,71,72,75,77,80,81,83,88,90,91,98,109,110,123} Myocarditis was reported to be more common in patients who received the COVID-19 mRNA vaccine versus the non-mRNA vaccine, and it was also more common in patients who received the vaccine for the second time. It was also found to be more common in men and patients aged 16 to 39 years.^{124,125}

Non-mRNA vaccines (vector-based vaccines/inactivated vaccines)

A recent systematic review on myocarditis after COVID-19 vaccination reported only one case after Astra Zeneca, one case after Sputnik V injection, and one case after vector Johnson & Johnson, out of a total of 277 cases.¹²⁰ A 32-year-old female case developed myocarditis on the third day after receiving the first dose of the AstraZeneca. The patient started experiencing inappropriate exertional

tachycardia and exertional dyspnea.¹¹¹ A case report of myocarditis following the administration of the Janssen vaccine in a healthy, young male also has been reported.¹¹² A study in Brazil reported a 47-year-old African-American male patient with type 2 diabetes and a previous history of COVID-19 infection. He had heart failure as a result of myocarditis after the second dose of an inactivated COVID-19 vaccine.⁴⁵ Other studies reported no myocarditis incidence in a subject receiving inactivated COVID-19 vaccine.^{126,127} A population-based study also showed that mainly, two mRNA vaccines mRNA-1273 (Moderna) & BNT162b2 (Pfizer-BioNTech) were more associated with increased risks for myocarditis/pericarditis compared to all other vaccines forms including viral vector vaccines of Ad26.COV2.S (Janssen) and AstraZeneca.¹²⁸

Proposed mechanisms for COVID-19 vaccines induced- Myocarditis

The existence of modest residual quantities of double-strand RNA (dsRNA) in mRNA COVID-19 vaccine preparations has been documented.^{129,130} Double-strand RNA (dsRNA) is well-known for inducing immune-inflammatory responses. The presence of dsRNA in vaccine nanoparticles might be the source of the unsolved instances of myocarditis.^{129,130} Patients who have experienced a past or recent experience of myocarditis constitute a prospective "susceptible"

Table 2

Reviewing the severity of post-COVID-19 vaccination cardiac manifestations, treatments, and outcomes.

Cardiac event	Manifestations/diagnosis criteria	Treatment	Outcome	Incidence in vaccine groups
Myocarditis/ Pericarditis	Chest pain, pulmonary edema, inappropriate exertional tachycardia, exertional dyspnea The diagnosis of myocarditis was established after a cardiac MRI	Medication and rest(admission based on patient risk)	Patients felt better quickly and following an improvement in their symptoms, patients can typically resume their regular daily activities	70- 80% of the patients received the mRNA COVID-19 vaccine, while 20- 25% received other types. ^{29,124,125}
Takotsubo cardiomyopathy (TTC)	Chest pain, transitory left ventricular failure, electrocardiographic abnormalities, an increased troponin level, the lack of occlusive coronary artery disease	Admission to the hospital and supportive care	All patients recovered from their symptoms, patients can typically resume their regular daily activities	80% of the patients received the mRNA COVID-19 vaccine, while 20% received other types. ¹³⁴
Myocardial infarction (MI)	Chest pain/discomfort	Admission to the hospital and management based on guidelines	Some patients developed heart failure, some cardiogenic shock, some were intubated, and some had cardiovascular-related mortality	No exact statistics were found
vaccine-induced thrombotic thrombocytopenia (VITT)/ pulmonary embolism (PE)	Breathlessness, Pain in the chest or stomach, swelling or coldness in a leg, severe or worsening headache or blurred vision after vaccination, persistent bleeding, reddish or purplish spots, or blood blisters under the skin	Admission to the hospital, treatment with nonheparin anticoagulation, followed by a rapid increase in platelet count ^{102,106}	Thrombocytopenia associated, pulmonary embolism and portal vein thrombosis is more frequently in women under 55	Most frequently reported after the use of the Vaxzevria (AstraZeneca) vaccine(106), next after the use of Janssen, and rarely by the use of mRNA vaccines

population that poses a treatment problem. In this population, patients are discouraged from obtaining COVID-19 immunization in the first 6 months after the onset of illness or in the context of chronic or relapsing troponin release.¹³¹ Most patients who received care for myocarditis or pericarditis responded well to medication and rest, with benign clinical course. It is worth noting that individual and public health advantages of COVID-19 immunization outweigh the modest risk of myocarditis following vaccination which could be resolved usually within days or weeks.^{8,132}

Takotsubo cardiomyopathy (TTC)

Takotsubo cardiomyopathy (TTC) is an acute transient left ventricular systolic dysfunction, after physical or emotional stress that is in differential diagnosis with myocardial infarction. Adrenergic stimuli, coronary vasospasm, microvascular dysfunction, inflammation, and alteration in cellular metabolism have been proposed to be responsible for this entity.¹³³

mRNA vaccines

A systematic review study on the prevalence of TTC after receiving COVID-19 vaccines included 10 case reports and their results showed that 80% of the patients received the mRNA vaccines, while 20% received other non-mRNA vaccines.¹³⁴ According to their results, TTC happened more frequently in female subjects compared to male subjects (90% vs. 10%), and in half of the subjects, TTC occurred after receiving the first dose.¹³⁴ Boscolo et al. reported a TTC case related to a healthy 30-year-old Asian female subject following mRNA COVID-19 vaccination (Pfizer).⁴⁰ A case of an 80-year-old woman on maintenance hemodialysis who developed TTC 4 days after administration of the first dose of the Pfizer-BioNTech COVID-19 vaccine also has been reported,⁸⁵ and a 73-year-old woman with recently diagnosed myocardial infarction (MI) found to have TTC immediately a day after administration of mRNA Moderna vaccine.⁸⁶

Non-mRNA vaccines (vector-based vaccines/ inactivated vaccines)

There are reports of TTC after COVID-19.^{76,113} Three cases of TTC have been reported for vector-based vaccines; a case of TTC for chadox1 Nov-19 adenoviral vector vaccine (AstraZeneca) was reported

in a 72-year-old male subject.⁴⁶ Another case of TTC was also reported short term following AstraZeneca injection.⁵⁶ The third case reported by Stewart et al. was an unusual female case of TTC who was the first case of a patient on hemodialysis and showed TTC symptoms 8 days after receiving the second dose of the DNA ChadOX1 nCOV-19 (AZD122) vaccination.⁷⁶ TTC was verified based on the results, which included transitory left ventricular failure, electrocardiographic abnormalities, an increased troponin level, and the lack of occlusive coronary artery disease. We found no reports of TTC caused by inactivated COVID-19 vaccines. An exclusive systematic review of the TCC cases following COVID-19 vaccination also reported no cases after inactive COVID-19 vaccination.¹³⁴

Recommended mechanisms for COVID-19 vaccines induced-TTC

Most of the participants who experienced TTC were female, and their age range for DNA vaccine /vector-based vaccines was around 50 years old, but for mRNA vaccines, it was around 60 years old. Acute emotional or physical stress increases cortisol hormone and catecholamine levels and their bioavailability in the blood, which mediates many routes such as direct damage of muscle cells, microvascular malfunction, and pericardial coronary artery spasm that all of these pathways are associated with TTC.¹³⁵ TTC patients have impaired neural networks in limbic brain regions such as the amygdala, prefrontal cortex, and hippocampus during stress.¹³⁴ Risk factors for COVID-19 vaccine-TTC reported as sex, age, and anxiety about the vaccine.⁸⁶ The overall rate of TTC incidence after COVID-19 vaccination is rare, but can be life-threatening. Chest pain should be taken seriously as an alarming symptom.¹³⁴

Myocardial infarction (MI)

mRNA vaccines

A case-series study in the UK reported an increased risk of MI after BNT162b2 (Pfizer-BioNTech) mRNA vaccination.⁹³ Sung et al.⁹⁷ and Kunis et al.⁹⁶ reported 2 cases and 1 case of MI, occurred 24 h post-vaccination with mRNA vaccines respectively. A population-based study reported the short-term risk of severe cardiovascular events including MI in people aged 75 years or older following the administration of BNT162b2 mRNA COVID-19 vaccination.¹¹ A WHO report

also confirmed that vaccines related to MI, cardiac arrest, and circulatory collapse were observed in the age group >75 years.¹³⁶

Non-mRNA vaccines (vector-based vaccines/ inactivated vaccines)

A 40-year-old man with no history of cardiovascular disease manifested with retrosternal chest discomfort 8 days after receiving the ChAdOx1 nCoV-19 vaccination against COVID-19, ST elevation in the electrocardiogram and regional wall motion abnormality in echocardiography. His blood testing revealed a high level of D-dimer, a troponin of 3185 ng/L with a strongly positive platelet factor-4 (PF-4) antibody test. On coronary angiography, an obstruction of the left anterior descending coronary artery was discovered. His platelet counts increased after 6 days, and his PF-4 antibody, D-dimer, and troponin levels decreased. After 14 days, he was successfully discharged.⁹² Hsu et al. also reported a case of 33 years old male subject who presented acute ST-Segment elevation MI following ChAdOx1 nCoV-19 vaccination in Taiwan.⁹⁴

Recommended mechanisms for COVID-19 vaccines induced-MI

Some hypotheses can be made since there is currently no experiment being conducted to specifically examine the incidence of MI among recipients of the COVID-19 vaccine. First, it has been proposed that the thrombotic phenomenon following vaccination was caused by vaccine-induced thrombotic thrombocytopenia (VITT) as a possible mechanism, a condition related to heparin-induced thrombocytopenia.^{115,116} The second hypothesis is that after vaccination, a supply and demand mismatch occurs in a diseased cardiovascular system.¹³⁷ It is also possible that a vasospastic allergic MI known as Kounis syndrome occurred in response to COVID-19 vaccines.^{138,139} However, the pathogenic mechanism underlying most cases remains undetermined.¹¹⁷

Pulmonary hemorrhage/ pulmonary embolism/ thrombotic thrombocytopenia (VITT)

mRNA vaccines

Al-Rasbi et al. presented a 37-year-old man with myocarditis, pulmonary edema, and pulmonary hemorrhage 12 days after receiving the first dose of Pfizer mRNA COVID-19 vaccination. He responded favorably to a 5-day course of intravenous methylprednisolone and immunoglobulin.³⁴ A case-series study also reported a short-term risk of pulmonary embolism (PE) among French residents aged 75 years or older after receipt of the BNT162b2 mRNA injection.¹¹ A study in Italy also reported a combination of acute exacerbation of interstitial lung diseases and PE in an elderly patient after booster mRNA vaccination against COVID-19.¹⁰⁰ A study in Saudi Arabia also reported a 78-year-old case with PE one day after receiving the second dosage of the Pfizer vaccine.¹⁰³ Another case of a healthy 24-year-old young man with PE due to the Pfizer vaccine also reported that his symptoms started 6 h after administration of the second dose of vaccine.¹⁰⁴ Idiopathic pulmonary fibrosis also was found after the Pfizer vaccine which was successfully treated with a short course of glucocorticoids.¹⁰⁵

Non-mRNA vaccines (vector-based vaccines /inactivated vaccines)

VITT has emerged as a rare side effect of adenoviral vector-based vaccines against coronavirus disease 2019 (COVID-19) and is most frequently reported after the use of the Vaxzevria (AstraZeneca) vaccine.¹⁰⁶ A 73-year-old case with PE was reported two weeks after receiving inactivated COVID-19 vaccine.¹⁰² A study in Germany reported a case with life-threatening bilateral PE as a complication of vaccine-induced thrombotic thrombocytopenia (VITT) after the first dose of the Oxford-AstraZeneca vaccine.¹⁰¹ A rare case of small segmental PE and VITT was reported for a 47-year-old woman 0 days after receiving the AstraZeneca vaccination.¹⁰⁷ A case with VITT and PE was reported 13 days after receiving the single dose of Janssen

vaccines.¹⁰⁶ Based on early clinical suspicion, the patient was treated with corticosteroids and intravenous immunoglobulin, which resulted in a rapid increase in platelet count, allowing full-dose anticoagulation to be administered on time. However, intravenous immunoglobulin treatment may mask the ability of anti-platelet factor 4-heparin antibodies to bind and activate platelets in the presence of heparin, resulting in false-negative immunoassay functional test results.

Recommended mechanisms for COVID-19 vaccines induced-VITT

Antibodies that target platelet factor 4 (PF4, also known as CXCL4) are responsible for VITT. The low affinities of platelet Fc-IIa receptors to these antibodies, which are immunoglobulin G (IgG) molecules, activate platelets.^{140,141} Investigations are being conducted to determine the mechanism(s) by which the implicated vaccines cause the production of new antibodies (and/or immune stimulation of already-existing antibodies). According to an evolving model, the vaccine stimulates the formation of neoantigens (the first struck) and a systemic inflammatory response (the second struck), which together cause the production of anti-PF4 antibodies. Virus proteins from the HEK3 cell line and free DNA are examples of vaccine components that could bind to PF4 and change its conformation, creating a neoantigen. According to preliminary research, adenoviral hexon proteins bound to PF4 may be to blame.^{114,141,142}

Conclusion

Our study showed that myocarditis was the most reported post-COVID19 vaccination cardiac event. All reported cardiac events including myocarditis, TTC, MI, and VITT occurred most frequently after receiving mRNA vaccines (Moderna & Pfizer-BioNTech). In the case of vector-based vaccines and/or inactivated vaccines, the prevalence of myocarditis and TTC were lower. Myocarditis was also more common in men between the ages of 16 and 39. MI/cardiac arrest was observed in the age group >75 years and was very rare. There have been no reports of TTC occurring after the injection of inactivated COVID-19 vaccines. Finally, the personal and public health advantages of COVID-19 immunization much outweigh the modest cardiac risk of that, which usually disappears in a matter of days or weeks. Reporting bias, regarding more available mRNA vaccines in developed countries, may conflict these results.

Declaration of Competing Interest

The authors declare that they have no known competing financial interests or personal relationships that could have appeared to influence the work reported in this paper.

The authors declare the following financial interests/personal relationships which may be considered as potential competing interests:

References

- 1 Soleimani A, Soleimani Z. Presentation and outcome of congenital heart disease during COVID-19 pandemic: a review. *Curr Probl Cardiol.* 2022;47(1): 100905.
- 2 Hantoushzadeh S, Nabavian SM, Soleimani Z, Soleimani A. COVID-19 disease during pregnancy and peripartum period: a cardiovascular review. *Curr Probl Cardiol.* 2022;47(1): 100888.
- 3 Chandra A, Gurjar V, Qamar I, Singh N. Exploring potential inhibitor of SARS-CoV2 replicase from FDA approved drugs using insilico drug discovery methods. *J Biomol Struct Dyn.* 2021.
- 4 Xia S, Duan K, Zhang Y, Zhao D, Zhang H, Xie Z, et al. Effect of an inactivated vaccine against SARS-CoV-2 on safety and immunogenicity outcomes: interim analysis of 2 randomized clinical trials. *JAMA.* 2020;324(10):951–960.
- 5 Ho JS, Sia CH, Ngiam JN, Loh PH, Chew NW, Kong WK, et al. A review of COVID-19 vaccination and the reported cardiac manifestations. *Singapore Med J.* 2021.
- 6 Griffin MR, Braun MM, Bart KJ. What should an ideal vaccine postlicensure safety system be? *Am J Public Health.* 2009;99. Suppl 2(Suppl 2):S345–S50.
- 7 Hendren NS, Carter S, Grodin JL. Severe COVID-19 vaccine associated myocarditis: zebra or unicorn? *Int J Cardiol.* 2021;343:197–198.

- 8 Heymans S, Cooper LT. Myocarditis after COVID-19 mRNA vaccination: clinical observations and potential mechanisms. *Nat Rev Cardiol.* 2022;19(2):75–77.
- 9 Husby A, Hansen JV, Fosbøl E, Thiesson EM, Madsen M, Thomsen RW, et al. SARS-CoV-2 vaccination and myocarditis or myopericarditis: population based cohort study. *BMJ.* 2021;375: e068665.
- 10 Isaak A, Feisst A, Luetkens JA. Myocarditis following COVID-19 vaccination. *Radiology.* 2021;301(1):E378..-e9.
- 11 Jabagi MJ, Botton J, Bertrand M, Weill A, Farrington P, Zureik M, et al. Myocardial infarction, stroke, and pulmonary embolism after BNT162b2 mRNA COVID-19 vaccine in people aged 75 years or older. *JAMA.* 2022;327(1):80–82.
- 12 Pepe S, Gregory AT, Myocarditis Denniss AR. Pericarditis and cardiomyopathy after COVID-19 vaccination. *Heart Lung Circ.* 2021;30(10):1425–1429.
- 13 O'Callaghan KP, Blatz AM, Offit PA. Developing a SARS-CoV-2 vaccine at warp speed. *JAMA.* 2020;324(5):437–438.
- 14 Patone M, Mei XW, Handunnetthi L, Dixon S, Zaccardi F, Shankar-Hari M, et al. Risks of myocarditis, pericarditis, and cardiac arrhythmias associated with COVID-19 vaccination or SARS-CoV-2 infection. *Nat Med.* 2022;28(2):410–422.
- 15 Nambiema A, Sembajwe G, Lam J, Woodruff T, Mandrioli D, Chartres N, et al. A protocol for the use of case reports/studies and case series in systematic reviews for clinical toxicology. *Front Med.* 2021;8. (Lausanne).
- 16 Page MJ, McKenzie JE, Bossuyt PM, Boutron I, Hoffmann TC, Mulrow CD, et al. The PRISMA 2020 statement: an updated guideline for reporting systematic reviews. *BMJ.* 2021;372:n71.
- 17 Marshall M, Ferguson ID, Lewis P, Jaggi P, Gagliardo C, Collins JS, et al. Symptomatic acute myocarditis in 7 adolescents after Pfizer-BioNTech COVID-19 vaccination. *Pediatrics.* 2021;148(3).
- 18 Deb A, Abdelmalek J, Iwuji K, Nugent K. Acute myocardial injury following COVID-19 vaccination: a case report and review of current evidence from vaccine adverse events reporting system database. *J Prim Care Community Health.* 2021;12: 21501327211029230.
- 19 Welsh KJ, Baumblatt J, Chege W, Goud R, Nair N. Thrombocytopenia including immune thrombocytopenia after receipt of mRNA COVID-19 vaccines reported to the vaccine adverse event reporting system (VAERS). *Vaccine.* 2021;39(25):3329–3332.
- 20 Park J, Brekke DR, Bratinscak A. Self-limited myocarditis presenting with chest pain and ST segment elevation in adolescents after vaccination with the BNT162b2 mRNA vaccine. *Cardiol Young.* 2022;32(1):146–149.
- 21 Nassar M, Nso N, Gonzalez C, Lakhdar S, Alshamam M, Elshafey M, et al. COVID-19 vaccine-induced myocarditis: case report with literature review. *Diabetes Metab Syndr.* 2021;15(5): 102205.
- 22 Oster ME, Shay DK, Su JR, Gee J, Creech CB, Broder KR, et al. Myocarditis cases reported after mRNA-based COVID-19 vaccination in the US from December 2020 to August 2021. *JAMA.* 2022;327(4):331–340.
- 23 Shams P, Ali J, Saadia S, Khan AH, Sultan FAT, Tai J. COVID-19 BBIBP-CorV vaccine and transient heart block - A phenomenon by chance or a possible correlation - A case report. *Ann Med Surg (Lond).* 2021;71: 102956.
- 24 Mansour J, Short RG, Bhalla S, Woodard PK, Verma A, Robinson X, et al. Acute myocarditis after a second dose of the mRNA COVID-19 vaccine: a report of two cases. *Clin Imaging.* 2021;78:247–249.
- 25 Muthukumar A, Narasimhan M, Li Q-Z, Mahimainathan L, Hitto I, Fuda F, et al. In-depth evaluation of a case of presumed myocarditis after the second dose of COVID-19 mRNA vaccine. *Circulation.* 2021;144(6):487–498.
- 26 McLean K, Johnson TJ. Myopericarditis in a previously healthy adolescent male following COVID-19 vaccination: a case report. *Acad Emerg Med.* 2021;28(8):918–921.
- 27 Ammirati E, Cavalotti C, Milazzo A, Pedrotti P, Soriano F, Schroeder JW, et al. Temporal relation between second dose BNT162b2 mRNA COVID-19 vaccine and cardiac involvement in a patient with previous SARS-CoV-2 infection. *Int J Cardiol Heart Vasc.* 2021;34: 100774.
- 28 Cereda A, Conca C, Barbieri L, Ferrante G, Tumminello G, Lucreziotti S, et al. Acute myocarditis after the second dose of SARS-CoV-2 vaccine: serendipity or atypical causal relationship? *Anatol J Cardiol.* 2021;25(7):522–523.
- 29 Abu Mouch S, Roguin A, Hellou E, Ishai A, Shoshan U, Mahamid L, et al. Myocarditis following COVID-19 mRNA vaccination. *Vaccine.* 2021;39(29):3790–3793.
- 30 Aiba T, Ishibashi K, Hattori K, Wada M, Ueda N, Miyazaki Y, et al. Frequent premature ventricular contraction and non-sustained ventricular tachycardia after the SARS-CoV-2 vaccination in patient with implantable cardioverter defibrillator due to acquired long-QT syndrome. *Circ J.* 2021;85(11):2117.
- 31 Kim D, Choi JH, Jang JY, So O, Cho E, Choi H, et al. A case report for myopericarditis after BNT162b2 COVID-19 mRNA vaccination in a Korean young male. *J Korean Med Sci.* 2021;36(39):e277.
- 32 Kim HW, Jenista ER, Wendell DC, Azevedo CF, Campbell MJ, Darty SN, et al. Patients with acute myocarditis following mRNA COVID-19 vaccination. *JAMA Cardiol.* 2021;6(10):1196–1201.
- 33 Kim Y, Zhu Z, Kochar P, Gavigan P, Kaur D, Kumar A. A pediatric case of sensory predominant guillain-barré syndrome following COVID-19 vaccination. *Child Neurol Open.* 2022;9: 2329048x221074549.
- 34 Al-Rasbi S, Al-Maqbali JS, Al-Farsi R, MA AlShukaili, Al-Riyami MH, Z AlFalahi, et al. Myocarditis, pulmonary hemorrhage, and extensive myositis with rhabdomyolysis 12 days after first dose of Pfizer-BioNTech BNT162b2 mRNA COVID-19 vaccine: a case report. *Am J Case Rep.* 2022;23: e934399.
- 35 Alania-Torres E, Morillas-Climent H, García-Escrivá A, Vinuesa-Buitrón P, Poquet-Catalá I, Zorio E, et al. Case report: probable myocarditis after COVID-19 mRNA vaccine in a patient with arrhythmogenic left ventricular cardiomyopathy. *Front Cardiovasc Med.* 2021;8: 759119.
- 36 Ameratunga R, Woon ST, Sheppard MN, Garland J, Ondruschka B, Wong CX, et al. First identified case of fatal fulminant necrotizing eosinophilic myocarditis following the initial dose of the Pfizer-BioNTech mRNA COVID-19 vaccine (BNT162b2, Comirnaty): an extremely rare idiosyncratic hypersensitivity reaction. *J Clin Immunol.* 2022:1–7.
- 37 Aviram G, Viskin D, Topilsky Y, Sadon S, Shalmon T, Taieb P, et al. Myocarditis associated with COVID-19 booster vaccination. *Circ Cardiovasc Imaging.* 2022;15(2): e013771.
- 38 Bautista García J, Peña Ortega P, Bonilla Fernández JA, Cárdenas León A, Ramírez Burgos L, Caballero Dorta E. Acute myocarditis after administration of the BNT162b2 vaccine against COVID-19. *Rev Esp Cardiol (Engl Ed).* 2021;74(9):812–814.
- 39 Bengel CP, Kacapor R. A report of two cases of myocarditis following mRNA coronavirus disease 2019 vaccination. *Eur Heart J Case Rep.* 2022;6(1). yta004.
- 40 Boscolo Berto M, Spano G, Wagner B, Bernhard B, Häner J, Huber AT, et al. Takotsubo cardiomyopathy after mRNA COVID-19 vaccination. *Heart Lung Circ.* 2021;30(12):e119. -e20.
- 41 Bozkurt B, Kamat I, Hotez PJ. Myocarditis with COVID-19 mRNA vaccines. *Circulation.* 2021;144(6):471–484.
- 42 Caforio ALP. Receipt of mRNA vaccine against COVID-19 and myocarditis. *N Engl J Med.* 2021;385(23):2189–2190.
- 43 Chamling B, Vehof V, Drakos S, Weil M, Stalling P, Vahlhaus C, et al. Occurrence of acute infarct-like myocarditis following COVID-19 vaccination: just an accidental co-incidence or rather vaccination-associated autoimmune myocarditis? *Clin Res Cardiol.* 2021;110(11):1850–1854.
- 44 Choi S, Lee S, Seo JW, Kim MJ, Jeon YH, Park JH, et al. Myocarditis-induced Sudden Death after BNT162b2 mRNA COVID-19 Vaccination in Korea: case report focusing on histopathological findings. *J Korean Med Sci.* 2021;36(40):e286.
- 45 Riedel PG, Sakai VF, Toniasso SCC, Brum MCB, Fernandes FS, Pereira RM, et al. Heart failure secondary to myocarditis after SARS-CoV-2 reinfection: a case report. *Int J Infect Dis.* 2021;113:175–177.
- 46 Crane P, Wong C, Mehta N, Barlis P. Takotsubo (stress) cardiomyopathy after ChAdOx1 nCoV-19 vaccination. *BMJ Case Rep.* 2021;14(10).
- 47 D'Angelo T, Cattafi A, Carerj ML, Booz C, Ascenti G, Cicero G, et al. Myocarditis after SARS-CoV-2 vaccination: a vaccine-induced reaction? *Can J Cardiol.* 2021;37(10):1665–1667.
- 48 De Jesus ML, Yabut J, Kumar M, Meng J. Cardiac adverse reactions with COVID-19 vaccinations. *Cureus.* 2022;14(1):e21372.
- 49 Ehrlich P, Klingel K, Ohlmann-Knafo S, Hüttinger S, Sood N, Pickuth D, et al. Biopsy-proven lymphocytic myocarditis following first mRNA COVID-19 vaccination in a 40-year-old male: case report. *Clin Res Cardiol.* 2021;110(11):1855–1859.
- 50 Facetti S, Giraldi M, Vecchi AL, Rogiani S, Nassiacos D. [Acute myocarditis in a young adult two days after Pfizer vaccination]. *G Ital Cardiol (Rome).* 2021;22(11):891–893.
- 51 Foltran D, Delmas C, Flumian C, De Paoli P, Salvo F, Gautier S, et al. Myocarditis and pericarditis in adolescents after first and second doses of mRNA COVID-19 vaccines. *Eur Heart J Qual Care Clin Outcomes.* 2022;8(2):99–103.
- 52 Gellad WF. Myocarditis after vaccination against COVID-19. *BMJ.* 2021;375:n3090.
- 53 Giray D, Epeçan S. Acute myocarditis following COVID-19 mRNA vaccination: a paediatric case. *Cardiol Young.* 2022:1–3.
- 54 Goldman RD. Myocarditis and pericarditis after COVID-19 messenger RNA vaccines. *Can Fam Physician.* 2022;68(1):17–18.
- 55 Hasnie AA, Hasnie UA, Patel N, Aziz MU, Xie M, Lloyd SG, et al. Perimyocarditis following first dose of the mRNA-1273 SARS-CoV-2 (Moderna) vaccine in a healthy young male: a case report. *BMC Cardiovasc Disord.* 2021;21(1):375.
- 56 Jani C, Leavitt J, Al Omari O, Dimaso A, Pond K, Gannon S, et al. COVID-19 vaccine-associated takotsubo cardiomyopathy. *Am J Ther.* 2021;28(3):361–364.
- 57 Khogali F, Abdelrahman R. Unusual presentation of acute perimyocarditis following SARS-CoV-2 mRNA-1237 moderna vaccination. *Cureus.* 2021;13(7):e16590.
- 58 King WW, Petersen MR, Matar RM, Budweg JB, Cuervo Pardo L, Petersen JW. Myocarditis following mRNA vaccination against SARS-CoV-2, a case series. *Am Heart J Plus.* 2021;8: 100042.
- 59 Levin D, Shimon G, Fadlon-Derai M, Gershovitz L, Shovali A, Sebbag A, et al. Myocarditis following COVID-19 vaccination - a case series. *Vaccine.* 2021;39(42):6195–6200.
- 60 Maki H, Aikawa T, Ibe T, Oyama-Manabe N, Fujita H. Biventricular systolic dysfunction in acute myocarditis after SARS-CoV-2 mRNA-1273 vaccination. *Eur Heart J Cardiovasc Imaging.* 2022;23(2):e87.
- 61 Mevorach D, Anis E, Cedar N, Bromberg M, Haas EJ, Nadir E, et al. Myocarditis after BNT162b2 mRNA Vaccine against COVID-19 in Israel. *N Engl J Med.* 2021;385(23):2140–2149.
- 62 Minocha PK, Better D, Singh RK, Hoque T. Recurrence of acute myocarditis temporally associated with receipt of the mRNA coronavirus disease 2019 (COVID-19) vaccine in a male adolescent. *J Pediatr.* 2021;238:321–323.
- 63 Montgomery J, Ryan M, Engler R, Hoffman D, McClenathan B, Collins L, et al. Myocarditis following immunization with mRNA COVID-19 vaccines in members of the US military. *JAMA Cardiol.* 2021;6(10):1202–1206.
- 64 Mungmunpantip R, Wiwanitit V. Myocarditis following mRNA-based COVID-19 vaccines: correspondence. *Cardiology.* 2022.
- 65 Murakami Y, Shinohara M, Oka Y, Wada R, Noike R, Ohara H, et al. Myocarditis following a COVID-19 messenger RNA vaccination: a Japanese case series. *Intern Med.* 2022;61(4):501–505.
- 66 Nguyen TD, Mall G, Westphal JG, Weingartner O, Möbius-Winkler S, Schulze PC. Acute myocarditis after COVID-19 vaccination with mRNA-1273 in a patient with former SARS-CoV-2 infection. *ESC Heart Fail.* 2021;8(6):4710–4714.

- 67 Nunn S, Kersten J, Tadic M, Wolf A, Gonska B, Hüll E, et al. Case report: myocarditis after COVID-19 vaccination - case series and literature review. *Front Med*. 2022;9: 836620. (Lausanne).
- 68 Perez Y, Levy ER, Joshi AY, Virk A, Rodriguez-Porcel M, Johnson M, et al. Myocarditis following COVID-19 mRNA vaccine: a case series and incidence rate determination. *Clin Infect Dis*. 2021.
- 69 Rosner CM, Genovese L, Tehrani BN, Atkins M, Bakhshi H, Chaudhri S, et al. Myocarditis temporally associated with COVID-19 vaccination. *Circulation*. 2021;144(6):502–505.
- 70 Sadiq W, Waleed MS, Suen P, Chalhoub MN. Cardiopulmonary arrest after COVID-19 vaccination: a case report. *Cureus*. 2022;14(1):e21141.
- 71 Schauer J, Buddha S, Colyer J, Sagiv E, Law Y, Mallenahalli Chikkabyrappa S, et al. Myopericarditis after the pfizer messenger ribonucleic acid coronavirus disease vaccine in adolescents. *J Pediatr*. 2021;238:317–320.
- 72 Schmitt P, Demoulin R, Poyet R, Capilla E, Rohel G, Pons F, et al. Acute myocarditis after COVID-19 vaccination: a case report. *Rev Med Interne*. 2021;42(11):797–800.
- 73 See I, Lale A, Marquez P, Streiff MB, Wheeler AP, Tepper NK, et al. Case series of thrombosis with thrombocytopenia syndrome after COVID-19 vaccination-United States. *Ann Intern Med*. 2021:2022.
- 74 Sánchez van Kammen M, Heldner MR, Brodard J, Scutelnic A, Silvis S, Schroeder V, et al. Frequency of thrombocytopenia and platelet factor 4/heparin antibodies in patients with cerebral venous sinus thrombosis prior to the COVID-19 pandemic. *JAMA*. 2021;326(4):332–338.
- 75 Simone A, Herald J, Chen A, Gulati N, Shen AY, Lewin B, et al. Acute myocarditis following COVID-19 mRNA vaccination in adults aged 18 years or older. *JAMA Intern Med*. 2021;181(12):1668–1670.
- 76 Stewart C, Gamble DT, Dawson D. Novel case of takotsubo cardiomyopathy following COVID-19 vaccination. *BMJ Case Rep*. 2022;15(1).
- 77 Tailor PD, Feighery AM, El-Sabawi B, Prasad A. Case report: acute myocarditis following the second dose of mRNA-1273 SARS-CoV-2 vaccine. *Eur Heart J Case Rep*. 2021;5(8):ytab319.
- 78 Toida R, Uezono S, Komatsu H, Toida T, Imamura A, Fujimoto S, et al. Takotsubo cardiomyopathy after vaccination for coronavirus disease 2019 in a patient on maintenance hemodialysis. *CEN Case Rep*. 2021:1–5.
- 79 Vidula MK, Ambrose M, Glassberg H, Chokshi N, Chen T, Ferrari VA, et al. Myocarditis and other cardiovascular complications of the mRNA-based COVID-19 vaccines. *Cureus*. 2021;13(6):e15576.
- 80 Verma AK, Lavine KJ, Lin CY. Myocarditis after COVID-19 mRNA vaccination. *N Engl J Med*. 2021;385(14):1332–1334.
- 81 Visclosky T, Theyyanni N, Klekowski N, Bradin S. Myocarditis following mRNA COVID-19 vaccine. *Pediatr Emerg Care*. 2021;37(11):583–584.
- 82 Viskin D, Topilsky Y, Aviram G, Mann T, Sadon S, Hadad Y, et al. Myocarditis associated with COVID-19 Vaccination: echocardiography, cardiac tomography, and magnetic resonance imaging findings. *Circ Cardiovasc Imaging*. 2021;14(9):e013236.
- 83 Watkins K, Griffin G, Septaric K, Simon EL. Myocarditis after BNT162b2 vaccination in a healthy male. *Am J Emerg Med*. 2021;50:815.. e1–e2.
- 84 Yap J, Tham MY, Poh J, Toh D, Chan CL, Lim TW, et al. Pericarditis and myocarditis after COVID-19 mRNA vaccination in a nationwide setting. *Ann Acad Med Singap*. 2022;51(2):96–100.
- 85 Toida R, Uezono S, Komatsu H, Toida T, Imamura A, Fujimoto S, et al. Takotsubo cardiomyopathy after vaccination for coronavirus disease 2019 in a patient on maintenance hemodialysis. *CEN Case Rep*. 2022;11(2):220–224.
- 86 Fearon C, Parwani P, Gow-Lee B, Abramov D. Takotsubo syndrome after receiving the COVID-19 vaccine. *J Cardiol Cases*. 2021;24(5):223–226.
- 87 Abbate A, Gavin J, Madanchi N, Kim C, Shah PR, Klein K, et al. Fulminant myocarditis and systemic hyperinflammation temporally associated with BNT162b2 mRNA COVID-19 vaccination in two patients. *Int J Cardiol*. 2021;340:119–121.
- 88 Azdaki N, Farzad M. Long QT interval and syncope after a single dose of COVID-19 vaccination: a case report. *Pan Afr Med J*. 2021;40:67.
- 89 Azir M, Inman B, Webb J, Mimic TL. STEMI: focal myocarditis in an adolescent patient after mRNA COVID-19 vaccine. *J Emerg Med*. 2021;61(6):e129.. e32.
- 90 Dickey JB, Albert E, Badr M, Laraja KM, Sena LM, Gerson DS, et al. A series of patients with myocarditis following SARS-CoV-2 vaccination with mRNA-1279 and BNT162b2. *JACC Cardiovasc Imaging*. 2021;14(9):1862–1863.
- 91 Dionne A, Sperotto F, Chamberlain S, Baker AL, Powell AJ, Prakash A, et al. Association of myocarditis with BNT162b2 messenger RNA COVID-19 vaccine in a case series of children. *JAMA Cardiol*. 2021;6(12):1446–1450.
- 92 Flower L, Bares Z, Santiapillai G, Harris S. Acute ST-segment elevation myocardial infarction secondary to vaccine-induced immune thrombosis with thrombocytopenia (VITT). *BMJ Case Rep*. 2021;14(9).
- 93 Hippisley-Cox J, Patone M, Mei XW, Saatci D, Dixon S, Khunti K, et al. Risk of thrombocytopenia and thromboembolism after COVID-19 vaccination and SARS-CoV-2 positive testing: self-controlled case series study. *BMJ*. 2021;374:n1931.
- 94 Hsu MH, Lee CP, Huang YC. Acute ST-segment elevation myocardial infarction after ChAdOx1 nCoV-19 vaccination in a 33-year-old man. *Ann Emerg Med*. 2022;79(2):220–221.
- 95 Istampoulouglou I, Dimitriou G, Späni S, Christ A, Zimmermanns B, Koechlin S, et al. Myocarditis and pericarditis in association with COVID-19 mRNA-vaccination: cases from a regional pharmacovigilance centre. *Glob Cardiol Sci Pract*. 2021;2021(3): e202118.
- 96 Kounis NG, Koniari I, Mplani V, Kouni SN, Plotas P, Tsigkas G. Acute myocardial infarction within 24 H After COVID-19 vaccination: is Kounis syndrome the culprit? *Am J Cardiol*. 2022;162:207.
- 97 Sung JG, Sobieszczyk PS, Bhatt DL. Acute Myocardial infarction within 24 H After COVID-19 vaccination. *Am J Cardiol*. 2021;156:129–131.
- 98 Larson KF, Ammirati E, Adler ED, Cooper Jr. LT, Hong KN, Saponara G, et al. Myocarditis after BNT162b2 and mRNA-1273 vaccination. *Circulation*. 2021;144(6):506–508.
- 99 Lazaros G, Anastassopoulou C, Hatziantoniou S, Kalos T, Soulaïdopoulos S, Lazarou E, et al. A case series of acute pericarditis following COVID-19 vaccination in the context of recent reports from Europe and the United States. *Vaccine*. 2021;39(45):6585–6590.
- 100 Bocchino M, Rea G, Buonocore A, Lieto R, Mazzocca A, Di Domenico A, et al. Combination of acute exacerbation of idiopathic nonspecific interstitial pneumonia and pulmonary embolism after booster anti-COVID-19 vaccination. *Respir Med Case Rep*. 2022;38: 101674.
- 101 Elkoumy M, Schoen J, Loew A. Management of a severe bilateral pulmonary embolism as a complication of VITT following vaccination with AstraZeneca COVID-19 vaccine. *BMJ Case Rep*. 2022;15(5).
- 102 Devi K, Ali N, Nasir N, Mahmood SF. VITT with inactivated SARS-CoV-2 vaccine - index case. *Hum Vaccin Immunother*. 2022;18(1): 2036556.
- 103 Alshammari F, Abuzied Y, Korairi A, Alajlan M, Alzomia M, AlSheef M. Bullous pemphigoid after second dose of mRNA- (Pfizer-BioNTech) COVID-19 vaccine: a case report. *Ann Med Surg (Lond)*. 2022;75: 103420.
- 104 Kyaw H, Shajahan S, Gulati A, Synn S, Khurana S, Nazar N, et al. COVID-19 mRNA vaccine-associated myocarditis. *Cureus*. 2022;14(1):e21009.
- 105 Ghincea A, Ryu C, Herzog EL. An acute exacerbation of idiopathic pulmonary fibrosis after BNT162b2 mRNA COVID-19 vaccination: a case report. *Chest*. 2022;161(2):e71.. e3.
- 106 Curcio R, Gandolfo V, Alcidi R, Giacomino L, Campanella T, Casarola G, et al. Vaccine-induced massive pulmonary embolism and thrombocytopenia following a single dose of Janssen Ad26.COV2.S vaccination. *Int J Infect Dis*. 2022;116:154–156.
- 107 Asmat H, Fayeye F, Alshakaty H, Patel J. A rare case of COVID-19 vaccine-induced thrombotic thrombocytopenia (VITT) involving the veno-splanchnic and pulmonary arterial circulation, from a UK district general hospital. *BMJ Case Rep*. 2021;14(9).
- 108 Türe M, Akın A, Demir M, Akay C. A paediatric case of myopericarditis post-COVID-19 mRNA vaccine. *Cardiol Young*. 2022:1–4.
- 109 Das BB, Kohli U, Ramachandran P, Nguyen HH, Greil G, Hussain T, et al. Myopericarditis after messenger RNA Coronavirus Disease 2019 Vaccination in Adolescents 12 to 18 Years of Age. *J Pediatr*. 2021;238:26–32. e1.
- 110 Koizumi T, Awaya T, Yoshioka K, Kitano S, Hayama H, Amemiya K, et al. Myocarditis after COVID-19 mRNA vaccines. *QJM*. 2021;114(10):741–743.
- 111 Hassanzadeh S, Sadeghi S, Mirdamadi A, Nematollahi A. Myocarditis following AstraZeneca (an adenovirus vector vaccine) COVID-19 vaccination: a case report. *Clin Case Rep*. 2022;10(4):e05744.
- 112 Sulemankhil I, Abdelrahman M, Negi SI. Temporal association between the COVID-19 Ad26.COV2.S vaccine and acute myocarditis: a case report and literature review. *Cardiovasc Revasc Med*. 2022;38:117–123.
- 113 Alizadehasl A, Soleimani A, Peighambari M, Mostafavi A. Biventricular apical ballooning in patient with COVID-19. *J Echocardiogr*. 2021.
- 114 Greinacher A, Selleng K, Palankar R, Wesche J, Handtke S, Wolff M, et al. Insights in ChAdOx1 nCoV-19 vaccine-induced immune thrombotic thrombocytopenia. *Blood*. 2021;138(22):2256–2268.
- 115 Greinacher A., Thiele T., Warkentin T.E., Weisser K., Kyrle P., Eichinger S. A prothrombotic thrombocytopenic disorder resembling heparin-induced thrombocytopenia following coronavirus-19 vaccination. 2021.
- 116 Baronti A, Gentile F, Manetti AC, Scatena A, Pellegrini S, Pucci A, et al. Myocardial infarction following COVID-19 vaccine administration: post hoc, ergo propter hoc? *Viruses*. 2022;14(8).
- 117 Aye YN, Mai AS, Zhang A, Lim OZH, Lin N, Ng CH, et al. Acute myocardial infarction and myocarditis following COVID-19 vaccination. *QJM*. 2021.
- 118 Grady KL, Costanzo-Nordin MR. Myocarditis: review of a clinical enigma. *Heart Lung*. 1989;18(4):347–353.
- 119 LeWinter MM. Clinical practice. Acute pericarditis. *N Engl J Med*. 2014;371(25):2410–2416.
- 120 Khan Z, Pabani UK, Gul A, Muhammad SA, Yousef Y, Abumedian M, et al. COVID-19 vaccine-induced myocarditis: a systemic review and literature search. *Cureus*. 2022;14(7):e27408.
- 121 Lota AS, Halliday B, Tayal U, Salmi S, Shakur R, Hammersley D, et al. Epidemiological trends and outcomes of acute myocarditis in the national health service of England. *Circulation*. 2019;140(Suppl_1):A11463.. -A.
- 122 In brief. Myocarditis with the Pfizer/BioNTech and moderna COVID-19 vaccines. *Med Lett Drugs Ther*. 2021;63(1629):e9.
- 123 Diaz GA, Parsons GT, Gering SK, Meier AR, Hutchinson IV, Robicsek A. Myocarditis and pericarditis after vaccination for COVID-19. *JAMA*. 2021;326(12):1210–1212.
- 124 Fazlollahi A, Zahmatyari M, Noori M, Nejadghaderi SA, Sullman MJM, Shekarriz-Foumani R, et al. Cardiac complications following mRNA COVID-19 vaccines: a systematic review of case reports and case series. *Rev Med Virol*. 2022;32(4): e2318.
- 125 Ling RR, Ramanathan K, Tan FL, Tai BC, Somani J, Fisher D, et al. Myopericarditis following COVID-19 vaccination and non-COVID-19 vaccination: a systematic review and meta-analysis. *Lancet Respir Med*. 2022;10(7):679–688.
- 126 Saeed BQ, Al-Shahrabi R, Alhaj SS, Alkorkhadi ZM, Adrees AO. Side effects and perceptions following Sinopharm COVID-19 vaccination. *Int J Infect Dis*. 2021;111:219–226.
- 127 Xia S, Zhang Y, Wang Y, Wang H, Yang Y, Gao GF, et al. Safety and immunogenicity of an inactivated SARS-CoV-2 vaccine, BBIBP-CoV: a randomised, double-blind, placebo-controlled, phase 1/2 trial. *Lancet Infect Dis*. 2021;21(1):39–51.

- 128 Li M, Yuan J, Lv G, Brown J, Jiang X, Lu ZK. Myocarditis and pericarditis following COVID-19 vaccination: inequalities in age and vaccine types. *J Pers Med.* 2021;11(11).
- 129 Milano G, Gal J, Creisson A, Chamorey E. Myocarditis and COVID-19 mRNA vaccines: a mechanistic hypothesis involving dsRNA. *Future Virol.* 2021.
- 130 Pardi N, Hogan MJ, Weissman D. Recent advances in mRNA vaccine technology. *Curr Opin Immunol.* 2020;65:14–20.
- 131 Sinagra G, Merlo M, Porcari A. Exploring the possible link between myocarditis and mRNA COVID-19 vaccines. *Eur J Intern Med.* 2021;92:28–30.
- 132 Haaf P, Kuster GM, Mueller C, Berger CT, Monney P, Burger P, et al. The very low risk of myocarditis and pericarditis after mRNA COVID-19 vaccination should not discourage vaccination. *Swiss Med Wkly.* 2021;151:w30087.
- 133 Singh T, Khan H, Gamble DT, Scally C, Newby DE, Dawson D. Takotsubo syndrome: pathophysiology, emerging concepts, and clinical implications. *Circulation.* 2022;145(13):1002–1019.
- 134 Ahmed S, Mohamed M, Essa R, Dabou E, Abdulqadir S, Muhammad Omar R. Global reports of takotsubo (stress) cardiomyopathy following COVID-19 vaccination: a systematic review and meta-analysis. *IJC Heart Vasc.* 2022;43: 101108.
- 135 Wittstein IS. The sympathetic nervous system in the pathogenesis of takotsubo syndrome. *Heart Fail Clin.* 2016;12(4):485–498.
- 136 Jeet Kaur R, Dutta S, Charan J, Bhardwaj P, Tandon A, Yadav D, et al. Cardiovascular adverse events reported from COVID-19 Vaccines: a study based on WHO database. *Int J Gen Med.* 2021;14:3909–3927.
- 137 Boivin Z, Martin J. Untimely myocardial infarction or COVID-19 vaccine side effect. *Cureus.* 2021;13(3).
- 138 Kounis NG, Mazarakis A, Tsigkas G, Giannopoulos S, Goudevenos J. Kounis syndrome: a new twist on an old disease. *Future Cardiol.* 2011;7(6):805–824.
- 139 Kounis NG, Koniari I, de Gregorio C, Velissaris D, Petalas K, Brinia A, et al. Allergic reactions to current available COVID-19 vaccinations: pathophysiology, causality, and therapeutic considerations. *Vaccines.* 2021;9(3):221.. (Basel).
- 140 Greinacher A, Thiele T, Warkentin TE, Weisser K, Kyrle PA, Eichinger S. Thrombotic thrombocytopenia after ChAdOx1 nCov-19 vaccination. *N Engl J Med.* 2021;384(22):2092–2101.
- 141 Huynh A, Kelton JG, Arnold DM, Daka M, Nazy I. Antibody epitopes in vaccine-induced immune thrombotic thrombocytopenia. *Nature.* 2021;596(7873):565–569.
- 142 Baker AT, Boyd RJ, Sarkar D, Teixeira-Crespo A, Chan CK, Bates E, et al. ChAdOx1 interacts with CAR and PF4 with implications for thrombosis with thrombocytopenia syndrome. *Sci Adv.* 2021;7(49):eab18213.